




# case study programme interim results

ARCHIMED CASE STUDY OXY CS001:  
THE USE OF OXYZYME® ON CHRONIC  
WOUNDS.

PART 4: MISCELLANEOUS CHRONIC  
WOUNDS



  
**Archimed™**  
A division of Insense Ltd.  
Colworth Science Park, Sharnbrook,  
Bedford, MK44 1LQ, UK

©Insense Ltd. April 2008  
[www.Archimed.co.uk](http://www.Archimed.co.uk)



**Archimed**<sup>™</sup>

A division of Insense Ltd.  
Colworth Science Park, Sharnbrook,  
Bedford, MK44 1LQ, UK

©Insense Ltd. April 2008  
[www.Archimed.co.uk](http://www.Archimed.co.uk)

# OXYZYME® CASE STUDY PROGRAMME

## OXY-CS001-01/01: THE USE OF OXYZYME® ON CHRONIC WOUNDS



### SUMMARY

- 11 year old female
- Progressive Dystrophic Epidermolysis Bullosa (EB)
- Wound on back has been present for 6 years
- Progress was apparent when OXYZYME™ applied directly to the wound
- **IMPROVED**

### PATIENT INFORMATION

Patient CC presented with a wound on her lower back, that she had had for 6 years. Medical History: Progressive Epidermolysis Bullosa (EB) Current Medication: Lansoprazole, Ferrous Fumarate, Cetirizine, Vallergan Previous Dressings: Mepilex and Mepitel. Honey.

### WOUND CONDITIONS

On entry into the case study the wound was described as a large lesion which was shallow wound with distinct wound margins.

### ASSESSMENTS

#### Week 1

After a week of OXYZYME™ being applied directly to the skin, a 75% reduction in wound area was observed.

The patient experienced pain on dressing change this is a common characteristic of the condition, and insisted on a resumption of the use of Mepitel as the wound contact layer.

#### Week 5

At the week 5 assessment, the wound was found to have increased by 9% compared to week 1

#### Week 7

At the week 8 assessment the wound had reverted to its previous state, doubling in size.

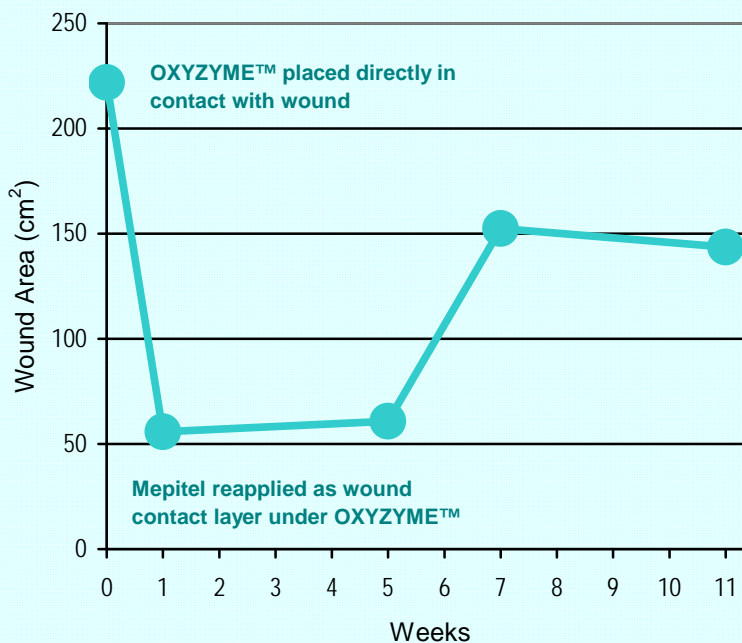


Fig. 1: Graph of change in wound area (measured by LUTM telemedicine software) with time.

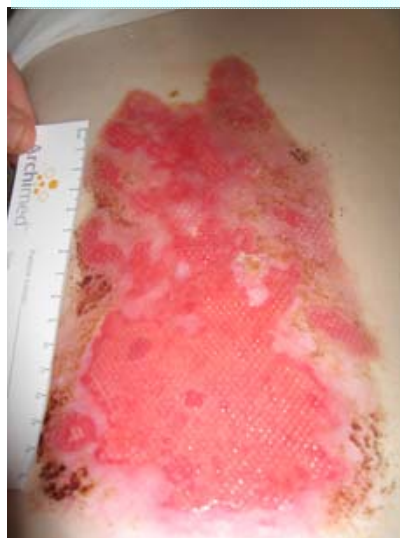

Fig. 2: Wound on entry

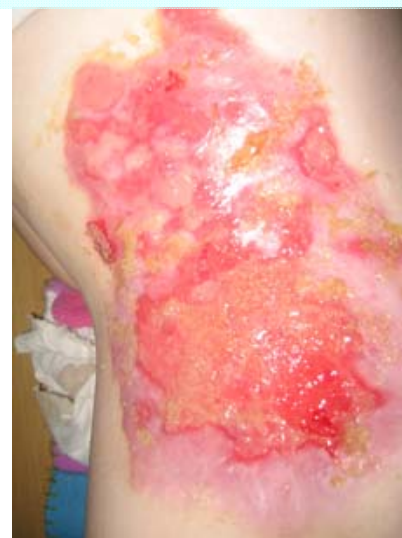

Fig. 3: after direct application of OXYZYME™ for one week.

#### Week 12

At the final assessment, the wound had again begun on a healing trajectory, reducing in size by 6%.

# OXYZYME<sup>®</sup> CASE STUDY PROGRAMME

## OXY-CS001-01/01: THE USE OF OXYZYME<sup>®</sup> ON CHRONIC WOUNDS



### COMMENT

Although by the end of the study the wound was reducing in size, the use of Mepitel, rather than OXYZYME<sup>™</sup>, as wound contact layer appeared to impair the healing rate, relative to the initial progress using OXYZYME<sup>™</sup> alone.

### SATISFACTION

The patient described mild discomfort throughout the case study but was generally satisfied with Oxyzyme<sup>™</sup>. The clinician noted that the patient did not scratch the affected area and that the dressing was easy to apply.

# OXYZYME<sup>®</sup> CASE STUDY PROGRAMME

## OXY-CS001-01/02: THE USE OF OXYZYME<sup>®</sup> ON CHRONIC WOUNDS



### SUMMARY

- 11 year old male with junctional epidermolysis bullosa (EB)
- Multiple lesions on legs, present for 5 years.
- The overall wound area increased slightly during the study but the condition of the wound bed improved and there was a reduction in odour and slough.
- **IMPROVED**

### PATIENT INFORMATION

Patient EM presented with multiple lesions on both legs. Current medication: piroxicam, morphine & paracetamol. Previous dressings: Mepitel and Mepilex Transfer.

### WOUND CONDITIONS

The lesions on the legs were often sloughy, with moderate levels of exudate and some malodour. All dressings were soaked off in the bath to prevent trauma and pain.

### ASSESSMENTS

#### Week 1

The wounds were dressed with Mepitel, Oxyzyme, Mepilex Transfer and Eclipse (Advancis). The wound margins were indistinct. The wound bed consisted of 20% slough and 80% granulation.

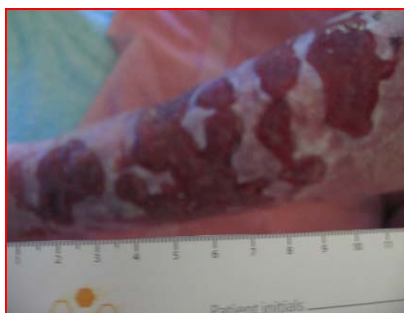


Fig 2. Wounds at week 1

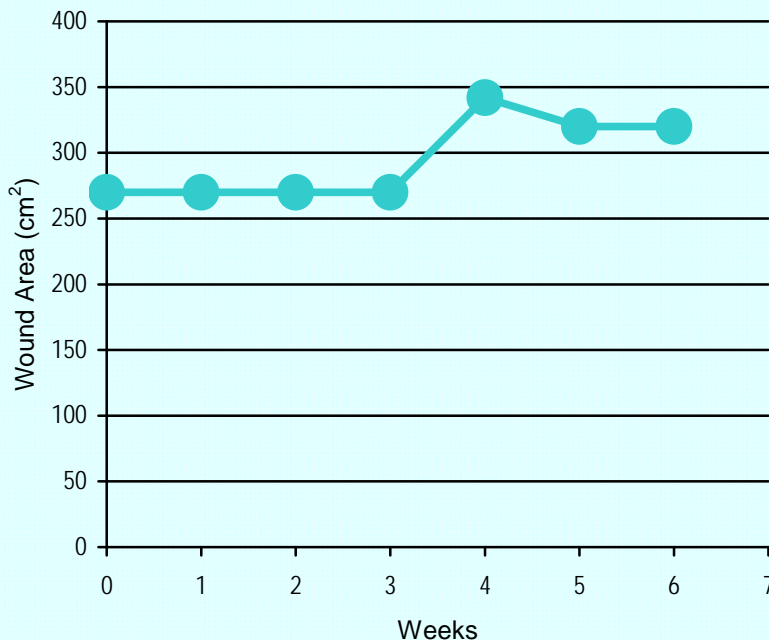


Fig. 1: Graph of change in wound area (as assessed by clinicians)

#### Week 3

The wound edges remained indistinct. The exudate was blood stained.

#### Week 6

The wound margins continue to be indistinct. Slough has lifted leaving the wounds larger in appearance but cleaner. Surrounding skin was macerated.

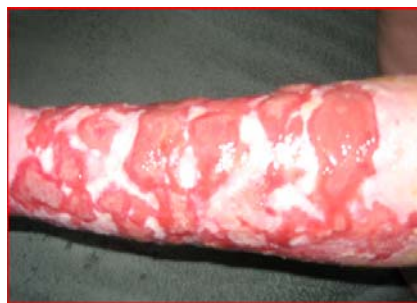

Fig 3. Wounds at week 6

### COMMENT

The wound size remained static and there was some improvement in the condition of the wounds (though the use of an occlusive cover dressing, Eclipse, may have reduced the effectiveness of the dressing).

### SATISFACTION

The clinicians reported that the dressing was easily removed with bathing and that there was a reduction in slough and odour during the case study. They also noted that it may cause discomfort on this type of chronic wounds.

The patient was generally satisfied with the Oxyzyme dressing.

**OXYZYME<sup>®</sup> CASE STUDY PROGRAMME**  
OXY-CS001-01/02: THE USE OF OXYZYME<sup>®</sup> ON  
CHRONIC WOUNDS



# OXYZYME® CASE STUDY PROGRAMME

## OXY-CS001-01/03: THE USE OF OXYZYME® ON CHRONIC WOUNDS



### SUMMARY

- **8 year old female**
- **Recessive dystrophic epidermolysis bullosa (EB)**
- **Wound duration 3 years**
- **Withdrawn due to bleeding**
- **DETERIORATED**

### PATIENT INFORMATION

Patient JW is an 8 year old female with a chronic lesion on her neck and chest of 3 years duration.

Medical History: recessive dystrophic epidermolysis bullosa.

Current Medication: trimeprazine, amitriptyline, domperidone, lansoprazole, ranitidine

Previous Dressings: Mepilex

### WOUND CONDITIONS

On entry into the case study programme the wound was described as a large shallow lesion located on the neck and chest. The wound measured 31cm<sup>2</sup>. The wound margins were indistinct. There was a moderate level of yellow wound exudate. The wound bed was described as a mixture of sloughy, granulation and epithelial tissue. The surrounding tissue was healthy.

Oxyzyme was applied directly to the skin and covered with Mepilex Boarder. The dressing was to be changed on a daily basis.

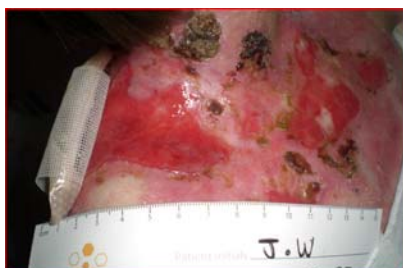


Fig.2. Wound on entry to study

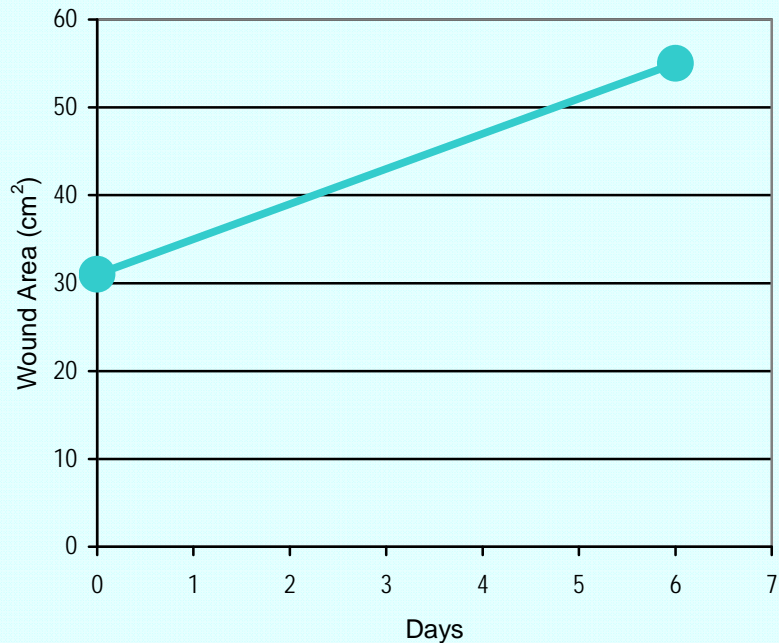


Figure 1: Wound area progress.

### ASSESSMENTS

#### Day 6

The wound had been redressed daily for 6 days when reviewed. An increase in wound size was noted by the clinician. No slough was present within the wound bed. 3 "blood blisters" were identified. There was a moderate level of blood stained wound exudate on the dressing. The patient was withdrawn from the study due to excessive bleeding.

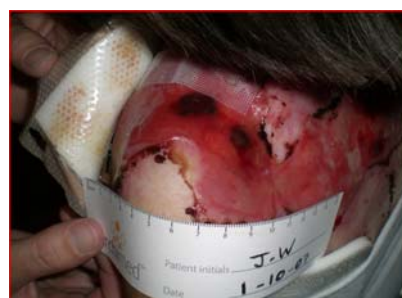

Fig. 3. Wound at day 6

### COMMENTS

The wound had been static for several months. At review on day 6 the wound had increased in size but was documented as being "less prominent". At dressing change on day 5 the wound bled profusely. Pressure was applied to the wound to stem the bleeding. According to the clinician there was no evidence of trauma occurring on dressing removal.

The clinician reviewed the wound 1 month later which had returned to the previous treatment regime and noted that the wound condition and size had improved since using Oxyzyme. The clinician noted that this may have been due to Oxyzyme "kick starting" the healing process.

# OXYZYME<sup>®</sup> CASE STUDY PROGRAMME

## OXY-CS001-01/03: THE USE OF OXYZYME<sup>®</sup> ON CHRONIC WOUNDS



### SATISFACTION

Children with epidermolysis bullosa often experience pain and trauma at dressing changes. Throughout the 6 days of treatment with Oxyzyme the patient found the dressing to be very comfortable at dressing change.

The patient was very satisfied with Oxyzyme up until the bleeding incident.

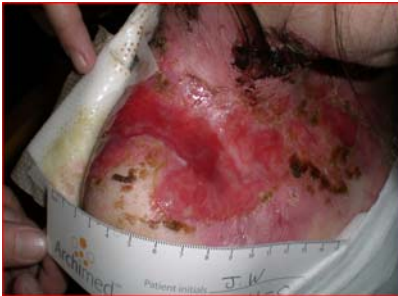


Fig.4. Wound at 1 month review

# OXYZYME<sup>®</sup> CASE STUDY PROGRAMME

## OXY-CS001-11/01: THE USE OF OXYZYME<sup>®</sup> ON CHRONIC WOUNDS



### SUMMARY

- **77 year old male**
- **Non healing surgical wound**
- **3 months duration**
- **HEALED**

### PATIENT INFORMATION

Patient RR is a 77 year old male with a non-healing surgical wound of 3 months duration. Medical History: Coronary Artery Bypass Graft, Diabetes Current Medication: Glicozide, Aspirin, Allopurinol, Quinine Previous Dressings: Aquacel Ag, Duodern Extra Thin.

### WOUND CONDITIONS

On entry into the case study the wound was described as a shallow non-healing surgical wound with distinct wound margins. Several small wounds were located along the proximal side of the left foot. For the purpose of this case study only the top wound was included. Despite the wound being small (1.5cm<sup>2</sup>) the wound had been static for several months. The wound bed was assessed as 50% slough 50% healthy granulation. The surrounding tissue was dry.

50/50 emulsifier was applied to the surrounding tissue. Oxyzyme was applied to the wound and covered with Lyofoam. The wound was to be redressed twice a week.

### ASSESSMENTS

#### Week 1

There was no significant reduction in wound area. The clinician noted that the wound bed had become cleaner (90% granulation and 10% slough).

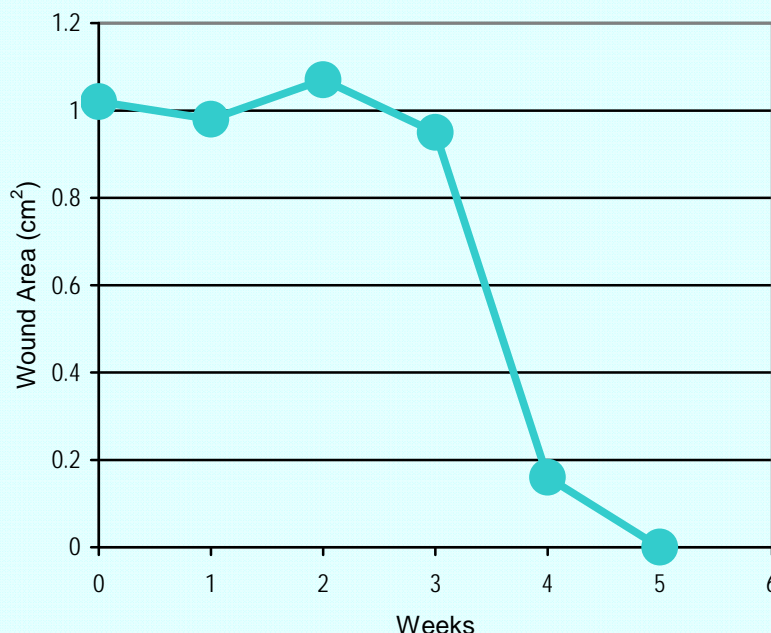


Figure 1: Wound area progress.

There was a low level of clear wound exudate. The surrounding tissue remained dry but healthy.

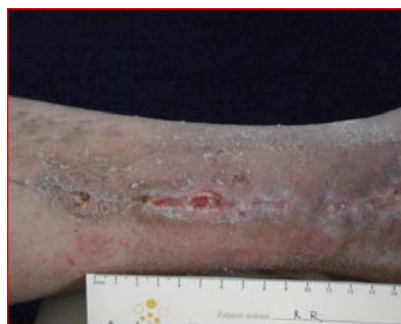

Fig. 2. Wound on entry to study

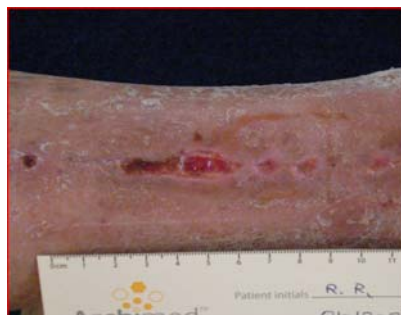

Fig. 3. Wound at week 1

#### Week 2

A slight increase in wound area was noted. The wound bed was assessed as 100% healthy granulation tissue. Exudate levels remain unchanged. The surrounding tissue remained dry.

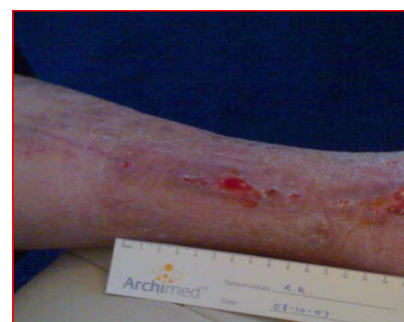

Fig.4. Wound at week 2

# OXYZYME® CASE STUDY PROGRAMME

## OXY-CS001-11/01: THE USE OF OXYZYME® ON CHRONIC WOUNDS



### Week 4

The clinician noted that the wound was almost healed. The wound bed remained 100% healthy granulation tissue. The surrounding tissue on the lower limb remained dry but healthy. A minimal amount of wound exudate was present.

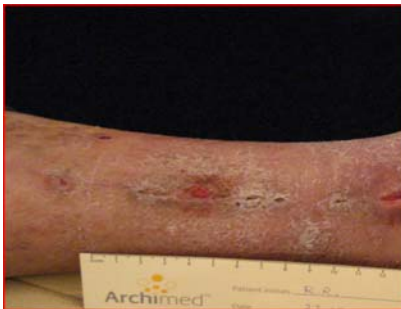

Fig. 5. Wound at Week 4

### Week 5

The wound was assessed by the clinician and recorded as healed.

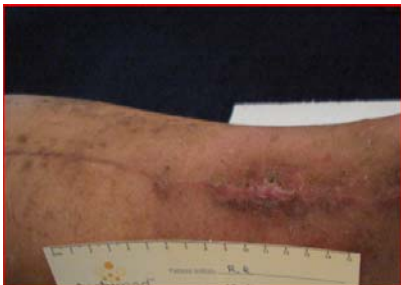

Fig. 6. Wound healed at week 5

### COMMENTS

The non-healing surgical wound had been static for several months. Following treatment with Oxyzyme for 5 weeks the wound was healed.

At the 4 week follow up the wound remained closed.

### SATISFACTION

The clinician recorded that Oxyzyme performed "much better" than dressings previously used on similar wounds.

The patient found the dressing to be "very comfortable" throughout the study and was "very satisfied" with the outcome.

# OXYZYME® CASE STUDY PROGRAMME

## OXY-CS001-18/01: THE USE OF OXYZYME® ON CHRONIC WOUNDS



### SUMMARY

- 70 year old female
- Surgical wound following failed peripheral arterial vascular graft
- Duration 2 years
- **HEALED**

### PATIENT INFORMATION

Patient AS is a 70 year old female who presented two wounds on the inner aspect of the left knee, from a failed peripheral arterial vascular graft (PAVG). This case study relates to the upper of the two wounds (a).

Medical History: Mild cardiac failure.

Current Medication: Digoxin, Aspirin, Frusemide.

Previous Dressings: larval therapy, VAC and Catrix.

### WOUND CONDITIONS

Initially, the wound was described as being a static shallow wound. The wound bed was assessed as being 100% granulation tissue. Low levels of serous wound exudate were documented. The surrounding tissue was healthy. The wound was measured at 6.5cm<sup>2</sup>.

### ASSESSMENTS

#### Week 1

At the first assessment, following a week of treatment with OXYZYME™ (secondary dressing gauze padding), the wound had reduced in size by 38%. The level of wound exudate remained low and clear in colour. The surrounding tissue remained healthy.

#### Week 2

The wound continued to decrease in size, being 54% smaller than the previous week.

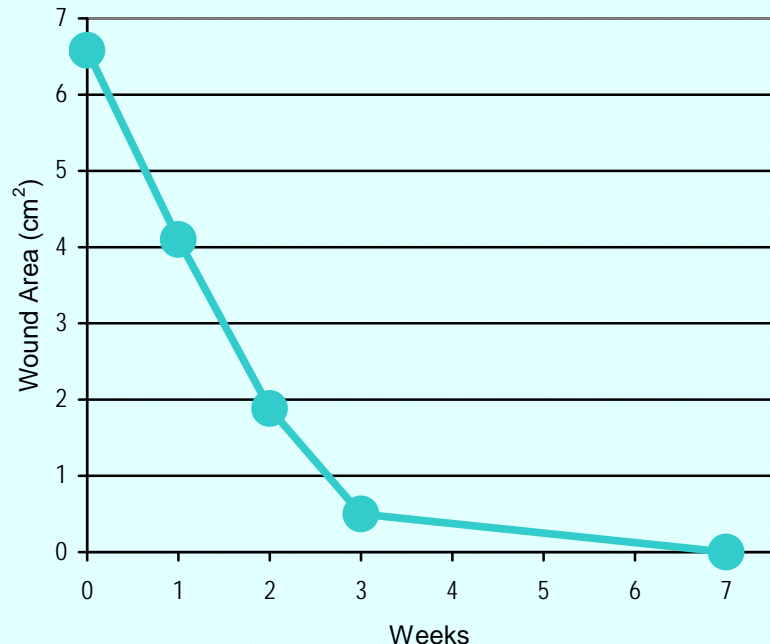


Fig. 1: Graph of change in wound area (measured by LUTM telemedicine software) with time.

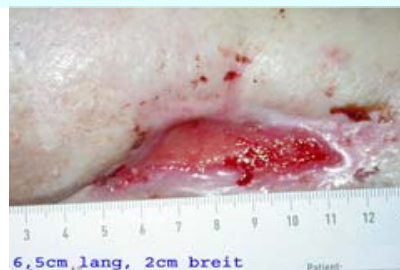

Fig. 2: Wound on entry

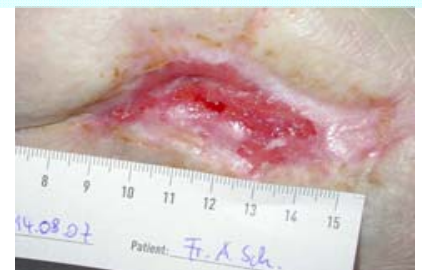


Fig. 3: Almost closed at week 3

#### Week 3

The wound reduced in size by a further 73% and the area was now less than 1cm<sup>2</sup>.

#### Week 7

The wound bed was covered 100% by epithelial tissue. The wound was documented as healed.

### SATISFACTION

The patient described Oxyzyme as very comfortable throughout the case study and was very satisfied with the outcome.

### COMMENTS

This wound had been static for several months prior to treatment with Oxyzyme and healed within 7 weeks.

**OXYZYME<sup>®</sup> CASE STUDY PROGRAMME**  
OXY-CS001-18/01: THE USE OF OXYZYME<sup>®</sup> ON  
CHRONIC WOUNDS



# OXYZYME<sup>®</sup> CASE STUDY PROGRAMME

## OXY-CS001-18/02: THE USE OF OXYZYME<sup>®</sup> ON CHRONIC WOUNDS



### SUMMARY

- 70 year old female
- Surgical wound following failed peripheral arterial vascular graft (PAVG).
- Wounds had been present for 2 years
- **HEALED**

### PATIENT INFORMATION

Patient AS is a 70 year old female who presented two wounds on the inner aspect of the left knee, from a failed peripheral arterial vascular graft (PAVG). This case study relates to the lower of the two wounds (b).

Medical History: mild cardiac failure.

Current Medication: Aspirin, Digoxin, Frusemide.

Previous treatments: larval therapy, VAC and Catrix.

### WOUND CONDITIONS

Initially, the wound was described as being a static shallow wound. The wound bed was assessed as 100% granulation tissue. There was a low level of serous wound exudate. The surrounding tissue was healthy. The wound measured 3cm<sup>2</sup>.

### ASSESSMENTS

#### Week 1

At the first assessment, following a week of treatment with OXYZYME<sup>™</sup>, the wound had reduced in size by 38%. The exudate levels remained low and clear in colour. The surrounding tissue remained healthy.

#### Week 2

The wound continued to decrease in size, being 82% smaller than the previous week.

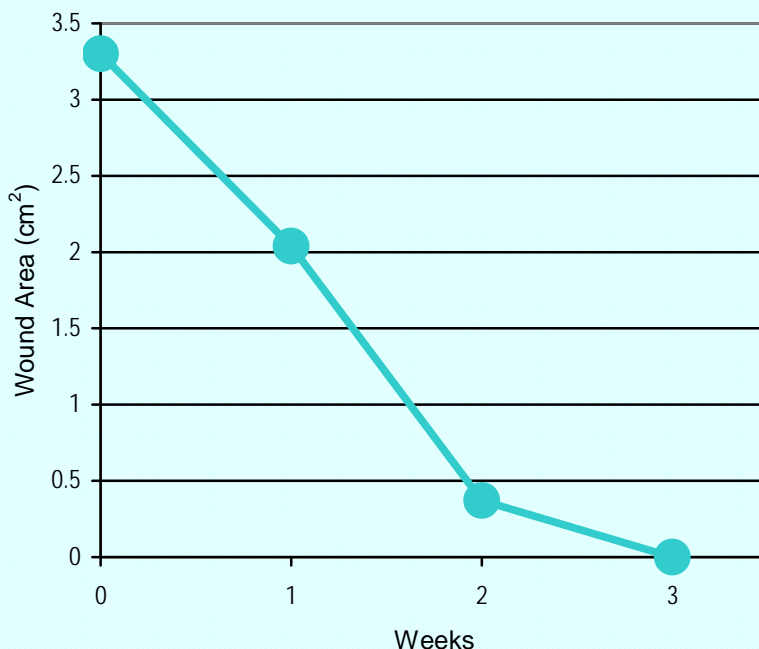


Fig. 1: Graph of change in wound area (measured by LUTM telemedicine software) with time.

#### Week 3

The wound bed was 100% epithelial tissue and was documented by the clinician to have healed.

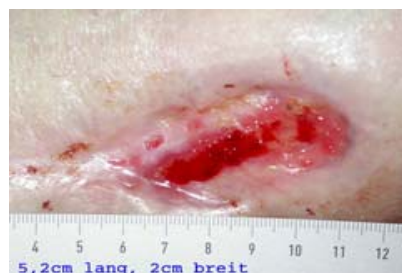

Fig. 2: Wound on entry

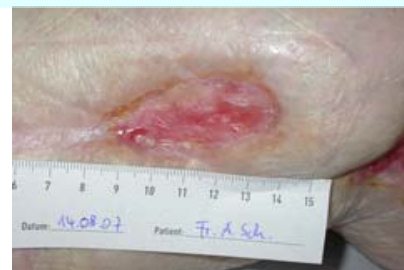

Fig. 3: Healed at week 3

### SATISFACTION

The patient described Oxyzyme<sup>™</sup> as very comfortable throughout the study and was very satisfied with the outcome.

### COMMENTS

The wound had been static for several months but healed within 3 weeks when treated with Oxyzyme.

**OXYZYME<sup>®</sup> CASE STUDY PROGRAMME**  
OXY-CS001-18/02: THE USE OF OXYZYME<sup>®</sup> ON  
CHRONIC WOUNDS



# OXYZYME<sup>®</sup> CASE STUDY PROGRAMME

## OXY-CS001-20/05: THE USE OF OXYZYME<sup>®</sup> ON CHRONIC WOUNDS



### SUMMARY

- 51 year old male
- Radionecrosis ulcer
- 3 months duration
- STATIC

### PATIENT INFORMATION

Patient OM presented with a radionecrosis ulcer on the left knee following radiotherapy. Medical History: Not known Current Medication: Not known Previous Dressings: Gauze

### WOUND CONDITIONS

On entry into the case study programme the wound was described as a shallow cavity measuring 3.3cm<sup>2</sup>. The wound bed was 100% healthy granulation tissue. There was a moderate level of clear wound exudate. The surrounding tissue was healthy.

The wound was dressed with Oxyzyme and covered with gauze. The wound was to be redressed twice a week.

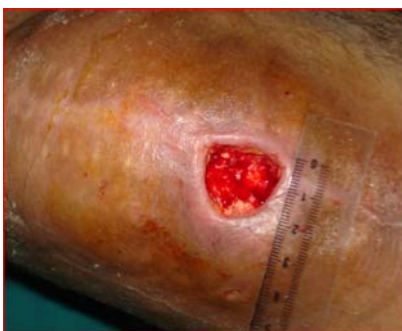

Fig.2. Wound on entry.

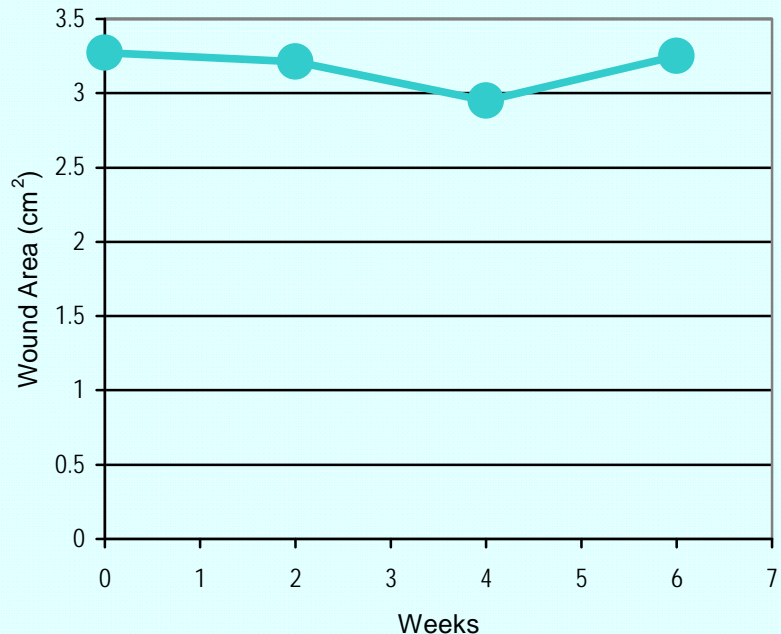


Figure 1. Wound area progress.

### ASSESSMENTS

#### Week 2

There was no significant reduction in wound area. The wound bed had become 80% granulating and 20% slough. There was a reduction in the level of clear wound exudate. The surrounding tissue continued to be reported as healthy.

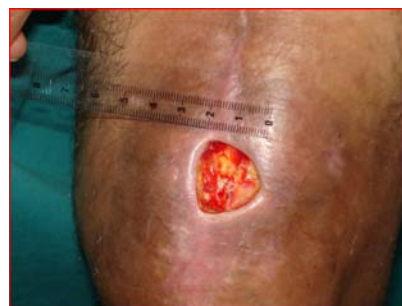

Fig.3. Wound at week 2.

#### Week 4

There was a reduction in wound area of 10%. The wound bed had become dehydrated containing approximately 50% granulation tissue and 50% slough. A further reduction in wound exudate was noted.

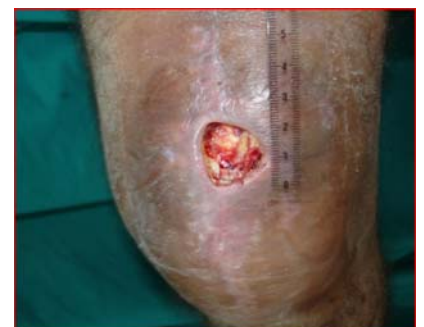

Fig.4. Wound at week 4.

# OXYZYME<sup>®</sup> CASE STUDY PROGRAMME

## OXY-CS001-20/05: THE USE OF OXYZYME<sup>®</sup> ON CHRONIC WOUNDS



### Week 6

The wound area returned to 3.25cm<sup>2</sup>. The wound bed was 50% granulation tissue and 50% dehydrated slough.

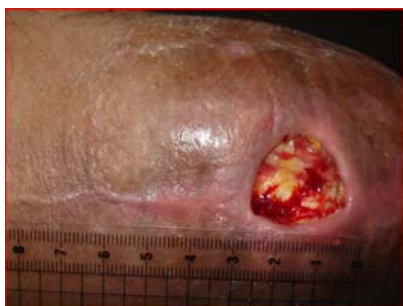

Fig.5. Wound at week 6

### COMMENTS

The wound remained static.

It is possible that this may have been due to the dehydrated condition of the wound bed. This may have been prevented by the use of a less absorbent dressing such as a film, rather than gauze.

### SATISFACTION

The clinician assessed that the Oxyzyme did not outperform previously used dressings.

The patient complained of mild discomfort during dressing change and the wearing of the dressing.