



# case study programme interim results

ARCHIMED CASE STUDY OXY CS001:  
THE USE OF OXYZYME® ON CHRONIC  
WOUNDS.

PART 2: DIABETIC FOOT ULCERS



**Archimed**<sup>™</sup>

A division of Insense Ltd.  
Colworth Science Park, Sharnbrook,  
Bedford, MK44 1LQ, UK

©Insense Ltd. April 2008  
[www.Archimed.co.uk](http://www.Archimed.co.uk)

# OXYZYME® CASE STUDY PROGRAMME

## OXY-CS001-07/01: THE USE OF OXYZYME® ON CHRONIC WOUNDS



### SUMMARY

- **46 year old male**
- **Diabetic foot ulcer**
- **18 month duration**
- **HEALED in 17 weeks**

### PATIENT INFORMATION

Patient RC is a 46 year old male with an 18 month old diabetic neuropathic foot ulcer.

Medical History: Type 1 diabetes, diabetic neuropathy, peripheral neuropathy, hypertension.

Current Medication: Frusemide, Actrapid.

Previous Dressings: Aquacel, Biatain.

### WOUND CONDITIONS

RC presented to the podiatry clinic with a diabetic neuropathic foot ulcer situated on his left heel. The wound was described as a shallow cavity wound with distinct wound margins. The wound bed was assessed to be 100% healthy granulation tissue. There was a moderate level of clear wound exudate. The surrounding wound tissue was described as healthy but slightly macerated. The wound had been static for several months. Oxyzyme was applied as the primary dressing and covered with Surgipad and bandage. The wound was to be redressed twice weekly. (All previous off loading methods remained unchanged).

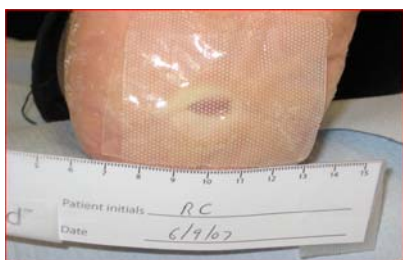

Fig.2. Wound dressed with Oxyzyme on entry to case study.

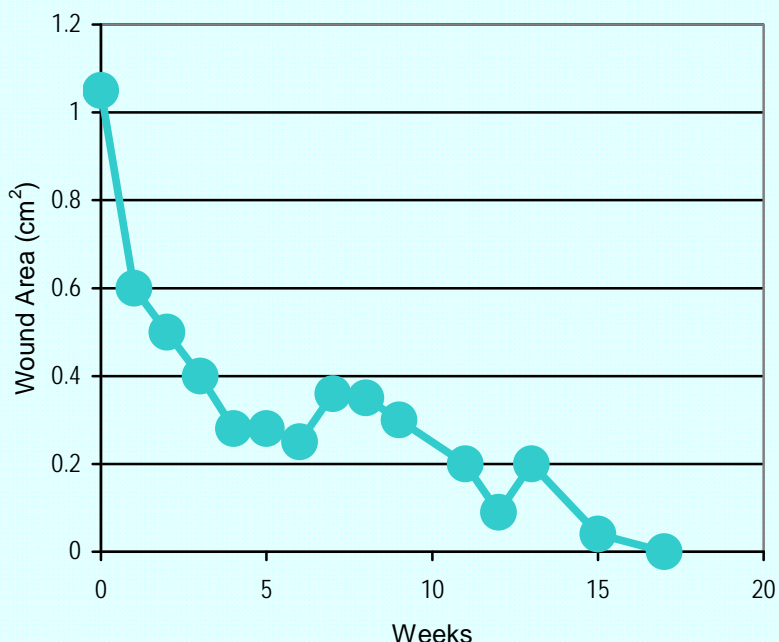


Figure 1. Progress of wound area (based on clinician's assessment).

### ASSESSMENTS

#### Week 1

Following treatment with Oxyzyme for 1 week the podiatrist documented a reduction in wound area of 43%. The wound bed was assessed to be epithelialising. A reduction in wound exudate was identified. Hæmoserous fluid was present. There was no change in the surrounding tissue.

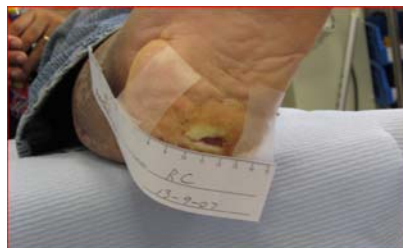

Fig.3. Wound at week 1

#### Week 3

The wound continues to reduce in size and depth. The podiatrist and the patient identified a significant reduction in wound

exudate. The surrounding tissue was assessed to be healthy.

#### Week 6

By week 6 there had been a total wound area reduction of 76%. The wound bed was assessed to be 100% healthy granulation tissue. The wound exudate was hæmoserous fluid which had increased slightly in amount. The increase in exudate had resulted in mild maceration of the wound margins.

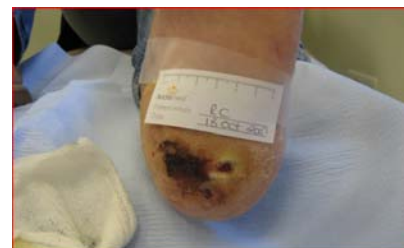

Fig.4. Wound at week 6

*continued overleaf...*

# OXYZYME<sup>®</sup> CASE STUDY PROGRAMME

## OXY-CS001-07/01: THE USE OF OXYZYME<sup>®</sup> ON CHRONIC WOUNDS



### Week 9

A further reduction in wound area was documented by the podiatrist. The wound bed remained healthy and granulating with epithelial tissue evident at the wound edges. The level of wound exudate had reduced and was now clear.

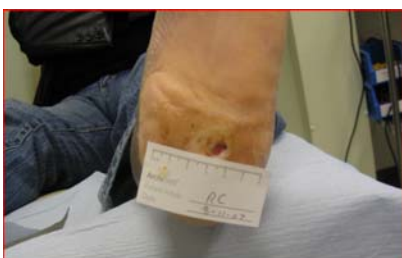

Fig.5. Wound at week 9.

### Week 15

The wound had very nearly healed, with an overall wound area reduction of 96%. The wound was epithelialising. There was no exudate. The wound margins and surrounding tissue were healthy.

### Week 17

The wound was assessed as healed by the podiatrist.



Fig.6. Wound healed at week 17

### COMMENTS

The wound had been present for 18 months and had been static for several months despite all other treatments. After treatment with Oxyzyme the wound healed in 17 weeks.

The podiatrist documented a significant reduction in wound exudate soon after commencing the Oxyzyme treatment as well as a reduction in malodour.

Interestingly, the patient reported an increase in sensation in and around the wound shortly after Oxyzyme treatment commenced.

### SATISFACTION

The patient was “very satisfied” with Oxyzyme throughout the treatment and found the dressing to be “very comfortable”.

The podiatrist described the dressing as much better than products previously used on similar types of wounds.

### HEALTH ECONOMICS COMPARISON

#### Cost of previous (unsuccessful) treatment over 18 months

Item	Cost
District Nurse Visit	£85.00
5x5cm Aquacel	£1.74
12x12cm Biatain adhesive	£2.29
<b>Total Procedure cost</b>	<b>£89.03</b>
Annual cost of treatment (twice weekly change)	£9,259
<b>Total treatment cost</b>	<b>£13,889</b>

#### Cost of healing using Oxyzyme<sup>™</sup> over 17 weeks

Item	Cost
District Nurse Visit	£85.00
10x10cm OXYZYME <sup>™</sup>	£10.00
1 Surgipad	£0.36
<b>Total Procedure cost</b>	<b>£95.36</b>
Cost of treatment to healing	£3,242

# OXYZYME® CASE STUDY PROGRAMME

## OXY-CS001-07/02: THE USE OF OXYZYME® ON CHRONIC WOUNDS



### SUMMARY

- **67 year old male**
- **Diabetic foot ulcer**
- **Duration 5 Months**
- **57% reduction in wound area**
- **IMPROVED**

### PATIENT INFORMATION

Patient JB is a 67 year old male who presented with a diabetic foot ulcer on his left heel. The wound has been present since April 2007 following failed skin graft. The wound was deteriorating.

Medical History: Type 2 diabetes, myocardial infarction, surgery on heel, skin graft.

Current Medication: atorvastatin, ramapril, aspirin, carvedilol, spironolactone, frusemide, insulin.

Previous Dressings: Mepilex, Surgipad.

### WOUND CONDITIONS

On entry to the case study programme the wound was assessed to be a shallow cavity wound with distinct wound margins. The wound bed was described as 100% healthy granulation tissue. Exudate was moderate in amount and haemoserous in nature. There was some malodour present. The surrounding tissue was slightly macerated. The overall condition of the wound prior to commencing Oxyzyme was noted as deteriorating. The wound was measured to be 31cm<sup>2</sup>.

Oxyzyme was applied with a Surgipad and bandage. The wound was planned to be redressed twice a week.

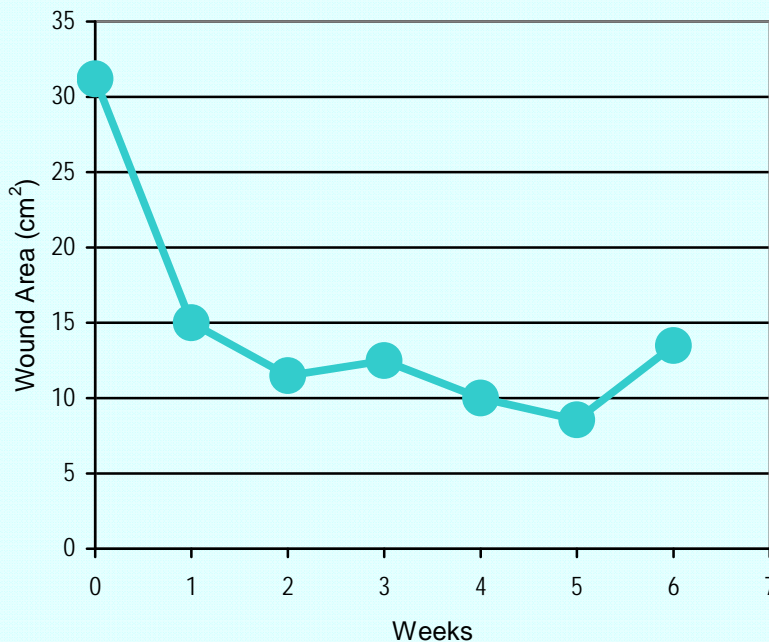


Figure 1: Graph of change in wound area (measured by Clinician) with time.

### ASSESSMENTS

#### Week 1

There was a significant reduction in wound area. The wound bed was described as 100% healthy granulation tissue. The exudate remained haemoserous in nature. The surrounding skin was healthy.

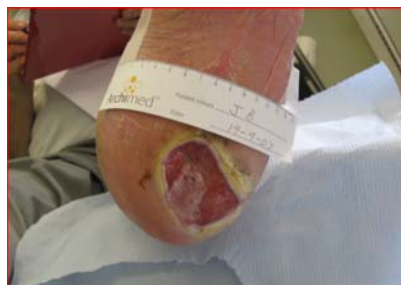

Fig.2. Wound on entry

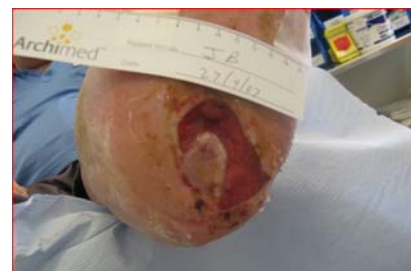

Fig.3. Wound at week 1

# OXYZYME<sup>®</sup> CASE STUDY PROGRAMME

## OXY-CS001-07/02: THE USE OF OXYZYME<sup>®</sup> ON CHRONIC WOUNDS



### Week 2

A further reduction in wound area was noted by the podiatrist. The wound bed continued to be 100% healthy granulation tissue. There was a reduction in haemoserous fluid. The surrounding tissue was slightly inflamed. A barrier cream was applied to the surrounding tissue.

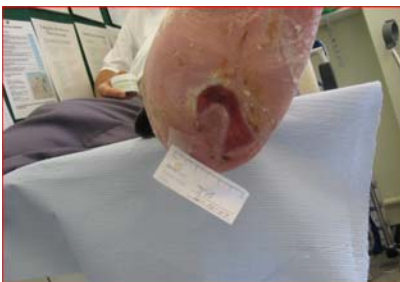

Fig.3.Wound at Week 2

### Week 4

The condition of the wound bed continued to improve. The wound bed was still 100% healthy granulation tissue. The surrounding tissue was healthy. The patient described an increase in sensation within and around the wound.

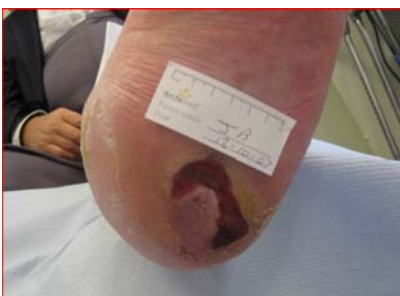

Fig.4.Wound at week 4

### Week 6

There was an increase in wound area of 35%. The wound bed remained 100% granulation tissue which appeared to be slightly darker in colour. Exudate levels remained reduced and haemoserous in nature. The surrounding tissue was assessed as healthy.

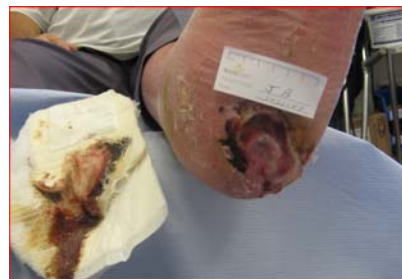

Fig.5.Wound at week 6

### COMMENTS

Overall there was a total wound area reduction of 57% over the 6 week period of the study. The patient was going on holiday for 6 weeks and was going to continue with Oxyzyme. The podiatrist noted that there was a significant reduction in wound exudate soon after starting the study. The patient also described an increase in sensation in and around the wound since beginning to use Oxyzyme.

### SATISFACTION

Throughout the study the patient was "very happy" with Oxyzyme and found it to be "very comfortable". The patient is happy to be able to go on holiday and continue with the Oxyzyme treatment.

The Podiatrist documented that Oxyzyme was "much better" than dressings previously used on similar wounds.

# OXYZYME® CASE STUDY PROGRAMME

## OXY-CS001-07/04: THE USE OF OXYZYME® ON CHRONIC WOUNDS



### SUMMARY

- **56 year old male**
- **Diabetic foot ulcer**
- **Duration 4 years**
- **Slight improvement in condition of wound & malodour declined**
- **STATIC**

### PATIENT INFORMATION

Patient RS is a 56 year old male who presented with a diabetic foot ulcer of 4 years duration. Medical History: Type 2 diabetes, Retinopathy, Hypothyroidism Current Medication: Glicazide, Thyroxine, Metformin, Simvastatin, Aspirin. Previous Dressings: Aquacel, Biatain.

### WOUND CONDITIONS

The wound was a diabetic foot ulcer situated on the left heel. The wound measured 3cm<sup>2</sup> on entry to the study. The wound was described as heavily exuding with slight malodour. The wound was a shallow cavity with distinct wound margins. The surrounding tissue was described as macerated. The wound bed was 100% healthy granulation tissue. The wound had been static for several months. A new pressure relieving boot was used 1 month previously. Oxyzyme was applied and covered with a surgipad. The wound was to be redressed every 2 days.

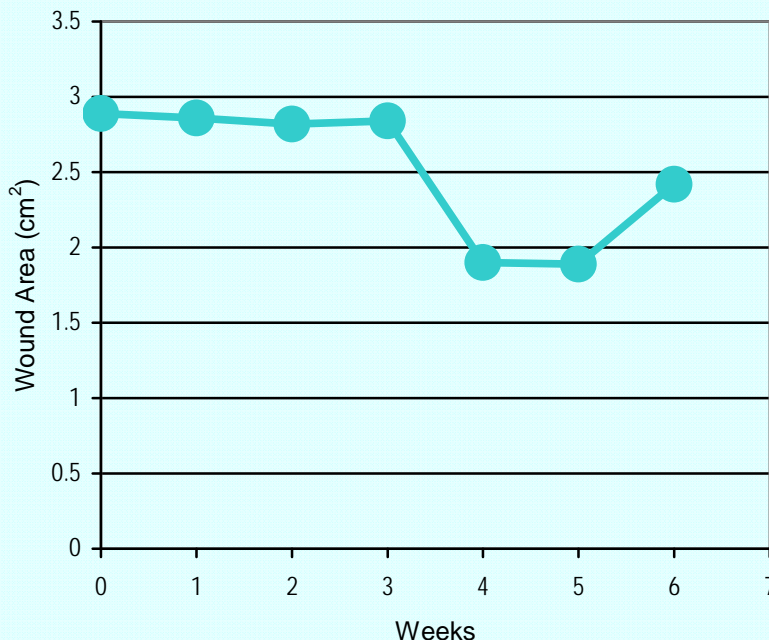
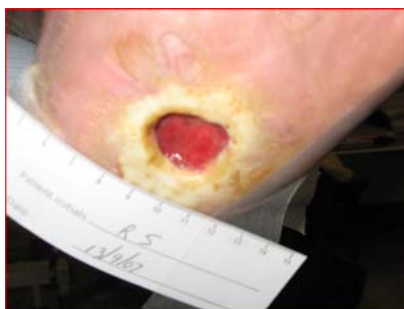

Figure 1: Wound area.

Fig.2.Wound on entry to study.

### ASSESSMENTS

#### Week 1

Following treatment with Oxyzyme for 1 week the wound was reassessed. The clinician noted a slight improvement in the general condition of the wound. Exudate levels remained high. Malodour was still evident. The surrounding tissue remained macerated.

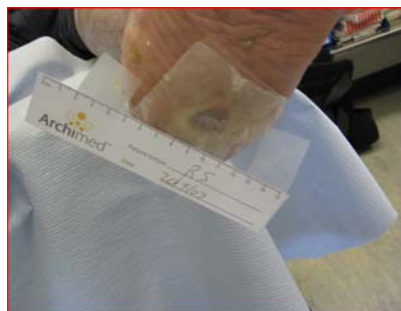

Fig.3. Wound at week 1 with Oxyzyme *in situ*.

#### Week 3

The wound remained static. Wound exudate levels remained high and haemoserous in nature. The surrounding tissue remained macerated. No malodour was reported.

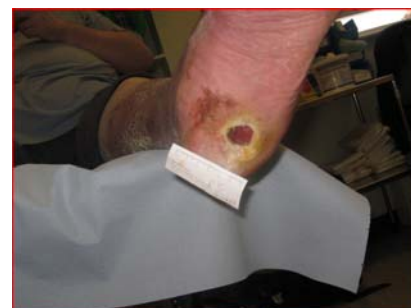

Fig.4. Wound at week 3.

# OXYZYME<sup>®</sup> CASE STUDY PROGRAMME

## OXY-CS001-07/04: THE USE OF OXYZYME<sup>®</sup> ON CHRONIC WOUNDS



### Week 4

A reduction in wound area of 34% was recorded. There was also a reduction in wound exudate. The surrounding tissue remains macerated.

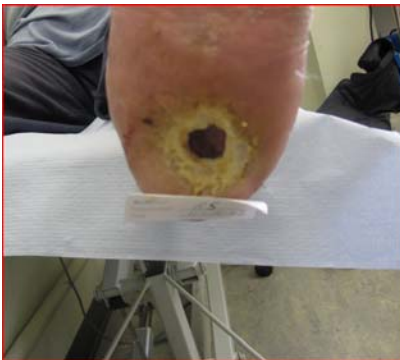


Fig.5. Wound at week 4.

### Week 6

There was an increase in wound area. The wound bed and exudate levels remained unchanged.

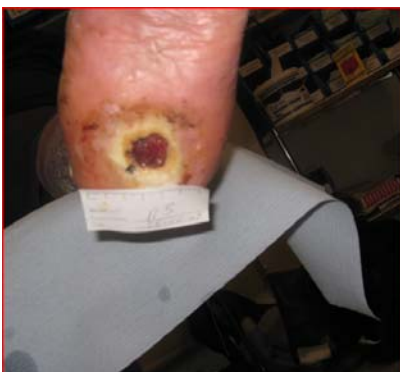

Fig.6. Wound at week 6

### COMMENTS

Following 6 weeks of treatment with Oxyzyme the clinician noted some slight improvement in the condition of the wound. The clinician considered that the lack of progress was due to the patient not wearing the prescribed Aircast boot and therefore not offloading pressure.

### SATISFACTION

The clinician assessed that Oxyzyme performed better on this wound than dressings previously used as the wound had remained static for several months and had become active when treated with Oxyzyme.

The patient described the dressing as "comfortable" or "very comfortable" and was generally satisfied with it.

# OXYZYME® CASE STUDY PROGRAMME

## OXY-CS001-07/05: THE USE OF OXYZYME® ON CHRONIC WOUNDS



### SUMMARY

- **66 Year Old male**
- **Diabetic Ulcer**
- **Duration 18 months**
- **IMPROVED**

### PATIENT INFORMATION

Patient BC is a 66 year old male who presented with a neuro-ischaemic diabetic ulcer situated on the site of a left below knee amputation

Medical History: Left and right below knee amputation, Type 1 diabetes, peripheral vascular disease.

Current Medication: Aspirin, Temazepam, Spironolactone, Atorvastatin, Ranitidine, Enalapril  
Previous Dressings: Honey

### WOUND CONDITIONS

On entry into the case study programme the wound was described as a shallow wound with distinct wound margins. There was a moderate level of clear wound exudate. The surrounding tissue was described as slightly inflamed but healthy. The wound bed was assessed as 60% slough, 40% healthy granulation tissue. The wound had been static for several months.

The wound was dressed with Oxyzyme and covered with a surgipad and bandage to secure. The dressing was to be changed twice a week.

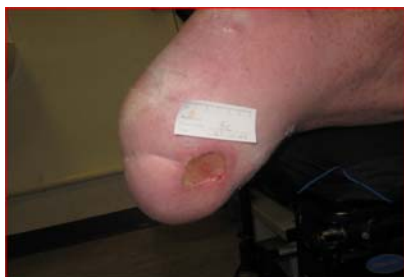

Fig.2.Wound on entry to case study

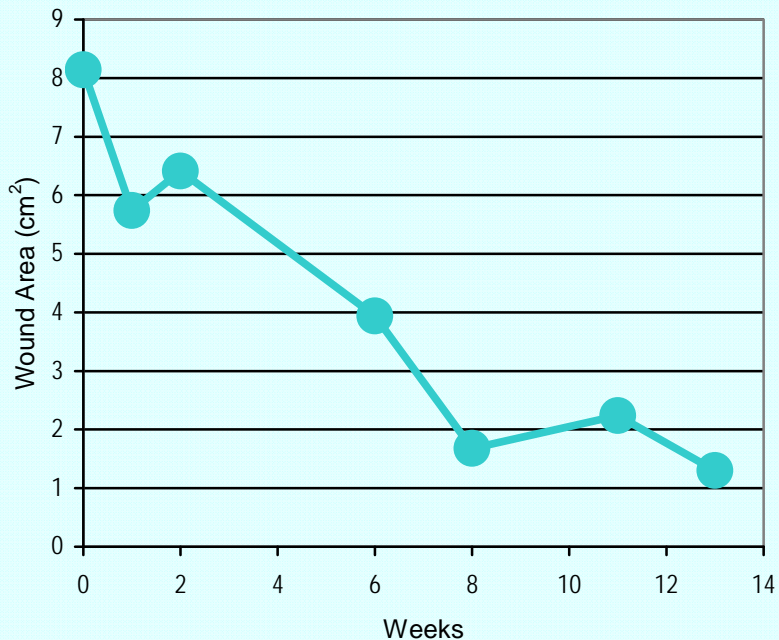


Figure 1: Graph of change in wound area with time.

### ASSESSMENTS

#### Week 1

There was a reduction in wound area of 29%. A significant improvement in the condition of the wound bed was documented (30% slough 70% granulation). Moderate levels of clear wound exudate continued. The surrounding tissue was assessed as healthy.

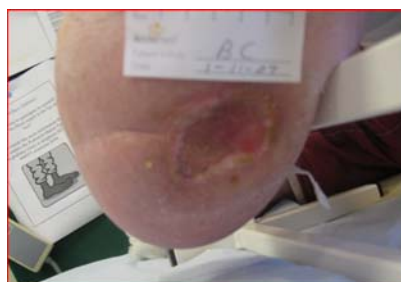

Fig.3.Wound at week 1

#### Week 2

There was a slight increase in wound area. The wound bed was assessed as 100% healthy granulation tissue. The surrounding tissue was healthy. There continued to be moderate levels of clear wound exudate.

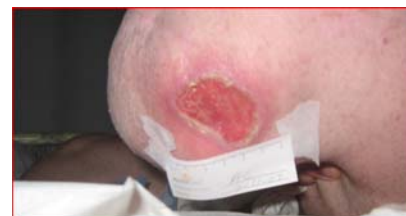

Fig.4.Wound at week 2

#### Week 3-5

BC was admitted into hospital following a myocardial infarct. No assessments were recorded during his hospital admission.

# OXYZYME<sup>®</sup> CASE STUDY PROGRAMME

## OXY-CS001-07/05: THE USE OF OXYZYME<sup>®</sup> ON CHRONIC WOUNDS



### Week 6

A further reduction in wound area was noted. The wound bed remained unchanged. The surrounding tissue was healthy. Exudate levels remained the same.

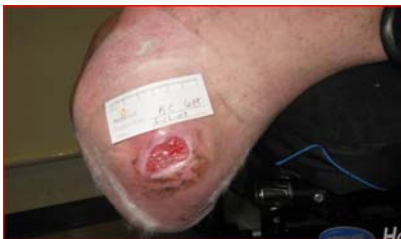

Fig.5.Wound at week 6

### Week 13

There was a reduction in wound area of 42%. The wound bed was 100% healthy granulation tissue. The surrounding tissue was healthy. There was a moderate level of clear wound exudate.

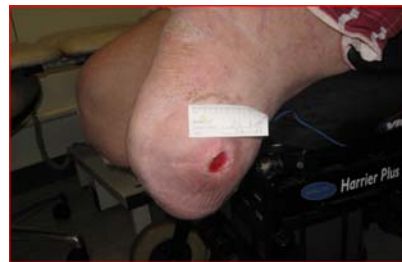

Fig.7.Wound at week 13

### Week 8

A significant reduction in wound area (57%) was noted. The wound bed remained 100% healthy granulation tissue. The wound exudate was moderate and haemoserous in nature.

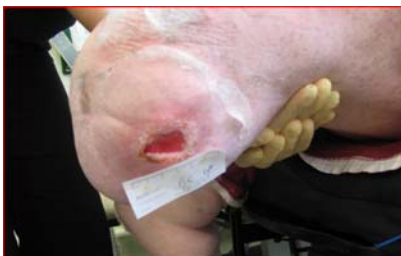

Fig.6.Wound at week 8

### Week 9-10

Over the Christmas period BC was seen by a different podiatrist, however the treatment regime remained the same.

### Week 11

There was a slight increase in wound area (33%). The wound bed remained 100% healthy. The wound exudate continued to be haemoserous in nature.

BC was admitted into hospital for a chest infection.

## COMMENTS

There was an overall reduction in wound area of 84%. BC was treated with Oxyzyme for 13 weeks with the intention of taking the wound on to healing as it was responding well to treatment. Unfortunately BC died.

## SATISFACTION

The patient was "very satisfied" with the performance of the Oxyzyme dressing and described it as "very comfortable".

The clinician reported that Oxyzyme out performed previous treatments used to manage similar types of wounds. The clinician reported that it was likely that the wound would have healed.

# OXYZYME® CASE STUDY PROGRAMME

## OXY-CS001-07/07: THE USE OF OXYZYME® ON CHRONIC WOUNDS



### SUMMARY

- **75 year old male**
- **Diabetic foot ulcer**
- **3 years duration**
- **Withdrawn due to hospitalisation**
- **SLIGHT IMPROVEMENT**

### PATIENT INFORMATION

Patient AM is a 75 year old male who presented with a diabetic foot ulcer on the plantar of Charcot foot.

Medical History: Type 2 diabetes, Peripheral neuropathy, Charcot foot, Hypertension, Retinopathy.  
Current Medication: Frusemide, Aspirin, Atorvastatin, Metformin.  
Previous Dressings: Biatain, Promogran, Hyalofill, Honey, Silver.

### WOUND CONDITIONS

On entry into the case study programme the wound measured 0.2 cm<sup>2</sup>. The wound had been static for several months. The wound was described as a shallow cavity with distinct wound margins which were healthy although slightly macerated. There was a moderate level of clear wound exudate. The wound bed was assessed as 100% healthy granulation tissue.

Oxyzyme was applied and covered with a surgipad and retention bandage. The Oxyzyme was changed twice a week.

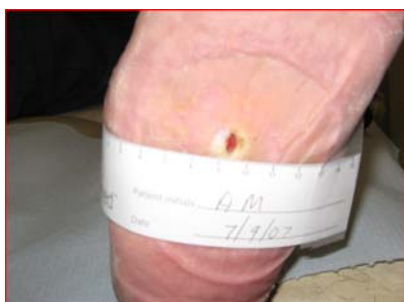

Fig.2. Wound on entry to study.

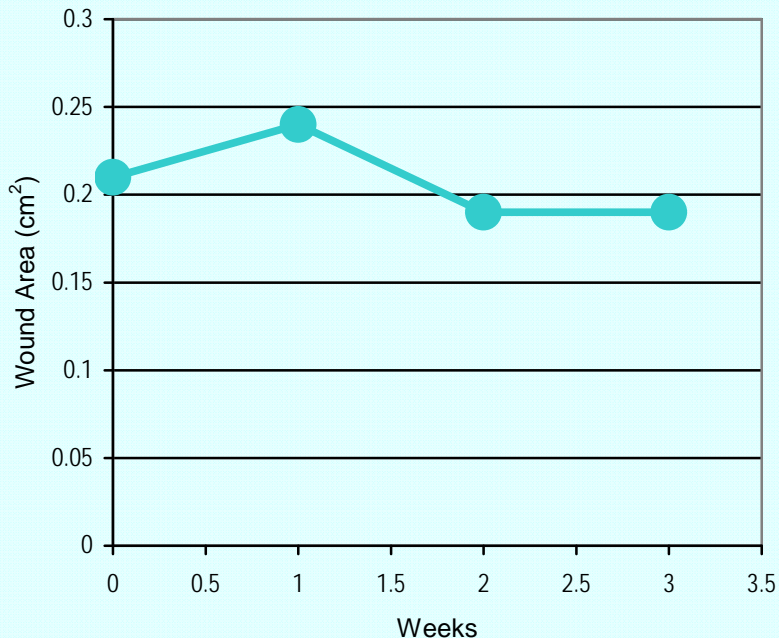


Figure 1: Wound area.

### ASSESSMENTS

#### Week 1

There was no significant change in wound area. The clinician and patient noted a reduction in wound exudate which was haemoserous in nature. The surrounding tissue was healthy with slight maceration. The wound bed continued to granulate.

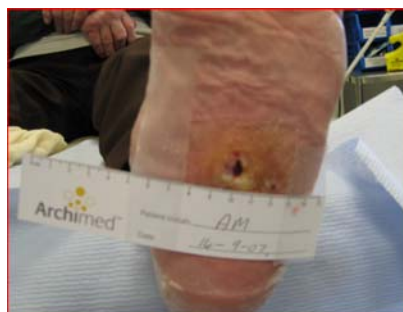

Fig.3. Wound at week 1.

#### Week 2

There was a slight reduction in wound area. The wound bed continued to granulate. Haemoserous exudate levels continued to reduce however the wound margins remained slightly macerated. Dressing change frequency increased to every 2 days.

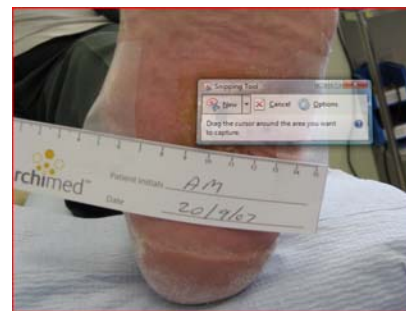

Fig.4. Wound at week 2.

# OXYZYME® CASE STUDY PROGRAMME

## OXY-CS001-07/07: THE USE OF OXYZYME® ON CHRONIC WOUNDS



### Week 3

There was no change in wound area. The wound bed was 100% healthy granulation tissue. Moderate levels of haemoserous fluid remained. The peri-wound skin was assessed to have become inflamed. The clinician considered this inflammation could be due to pressure damage.

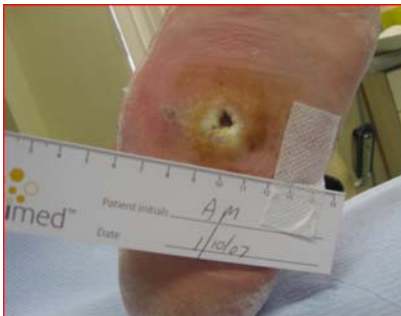

Fig.5.wound at week 3

### COMMENTS

The patient was admitted to hospital with cellulitis and discontinued from the case study.

The clinician commented that the wound which had been static for a long time had improved slightly during the 3 weeks of Oxyzyme treatment.

### SATISFACTION

The clinician reported that Oxyzyme performed "much better" than previous treatments. The patient was generally satisfied with Oxyzyme and found it to be very comfortable.

# OXYZYME® CASE STUDY PROGRAMME

## OXY-CS001-18/03: THE USE OF OXYZYME® ON CHRONIC WOUNDS



### SUMMARY

- 69 year old male
- Surgical wound following amputation of toes.
- Duration 6 months
- 66% Reduction in wound area
- **IMPROVED**

### PATIENT INFORMATION

Patient KH, a 69 year old male with 6 month old surgical wound following amputation of toes.  
Medical History: diabetes  
Current Medication: Aspirin

### WOUND CONDITIONS

The wound was 15cm<sup>2</sup> and the wound bed was 80% slough & 20% granulation tissue. Moderate level of blood stained exudate. Surrounding skin was healthy.

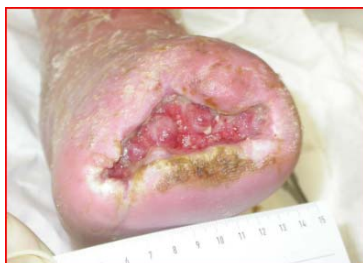

Fig 2.Wound on entry

### ASSESSMENTS

Cover dressing used during study: Urgotul

#### Week 1

50% slough & 50% granulation tissue. Exudate remained blood stained and moderate in amount.

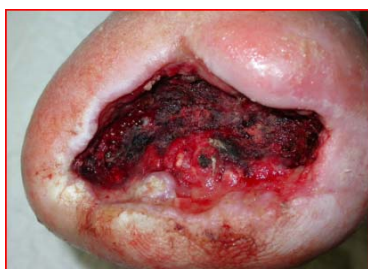

Fig 3.Wound at week 1

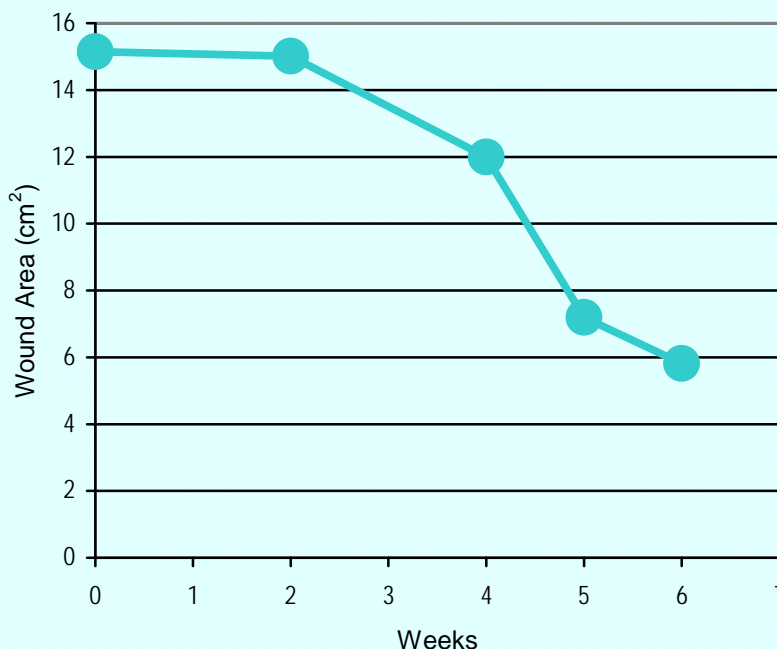


Fig. 1: Graph of change in wound area (measured by LUTM telemedicine software) with time.

#### Week 4

The wound was measured to be 12cm<sup>2</sup> (a reduction of 20%). The wound bed was assessed as 50% slough 50% granulation tissue. The exudate level remained moderate. Cavilon barrier film was applied to the surrounding skin.

#### Week 6

The wound area was measured at 5cm<sup>2</sup> (a further reduction of 58%). The wound bed was assessed as 100% granulation tissue. The surrounding tissue was healthy. Exudate was clear and levels had reduced slightly.

### COMMENT

This patient showed a significant improvement in the condition of his wound and a reduction in area of 66% over the 6 week study.

### SATISFACTION

The patient found the Oxyzyme dressing to be comfortable during application and wear.

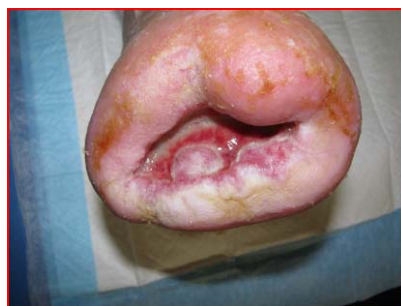

Fig 4.Wound at week 6

**OXYZYME<sup>®</sup> CASE STUDY PROGRAMME**  
OXY-CS001-18/03: THE USE OF OXYZYME<sup>®</sup> ON  
CHRONIC WOUNDS



# OXYZYME® CASE STUDY PROGRAMME

## OXY-CS001-18/06: THE USE OF OXYZYME® ON CHRONIC WOUNDS



### SUMMARY

- 67 year old male
- Diabetic foot ulcer
- Duration 1 year
- Reduction in wound area 90%
- **IMPROVED**

### PATIENT INFORMATION

Patient HR is a 67 year old male presenting with a diabetic foot ulcer of 1 year duration.

Medical History: hypertension, non insulin dependent diabetes (NIDDM), peripheral arterial bypass graft.

Current Medication: Diuretics and Anticoagulants

Previous dressing: Compress surgipad.

### WOUND CONDITIONS

On entry into the case study programme the wound measured 16cm<sup>2</sup>. The wound bed was assessed as 20% necrosis, 60% thick slough 20% granulation tissue. There was a moderate level of blood stained exudate.

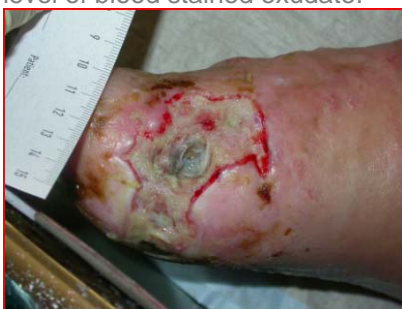

Fig.2. Wound on entry

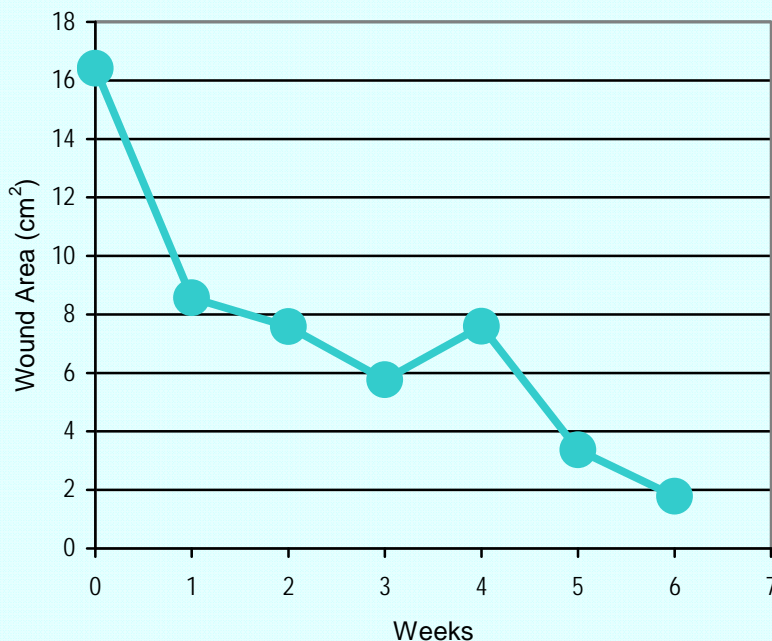


Figure 1: Graph of change in wound area (measured by LUTM telemedicine software) with time.

### ASSESSMENTS

#### Week 1

Following 1 week of treatment with Oxyzyme and Urgotul, the wound was measured at 8.5cm<sup>2</sup> a wound reduction of 47%. The wound was assessed as 80% granulation 20% slough. Moderate, blood stained exudate.

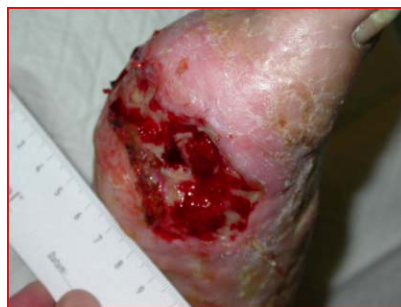

Fig.3. Wound at week 1

#### Week 2

The wound continued to reduce in size. The wound bed remained 20% slough 80% granulation tissue. There was a reduction in wound exudate. The surrounding tissue was dry and healthy.

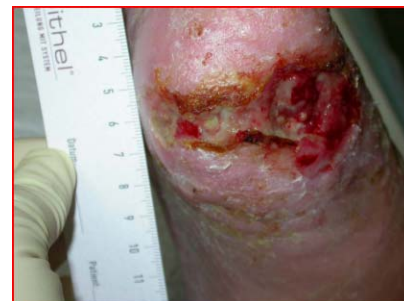

Fig.4. Wound at week 2

# OXYZYME<sup>®</sup> CASE STUDY PROGRAMME

## OXY-CS001-18/06: THE USE OF OXYZYME<sup>®</sup> ON CHRONIC WOUNDS



### Week 4

The wound measured 8cm<sup>2</sup>. The wound bed was assessed as 90% granulation tissue 10% loose slough. The wound depth had reduced and wound contraction could be seen.

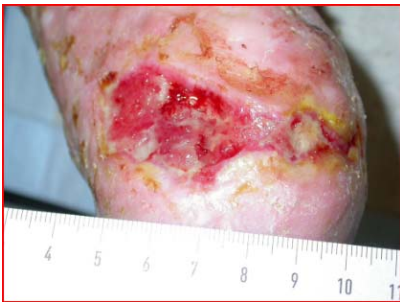

Fig.5. Wound at week 4

### Week 6

The wound measured 2cm<sup>2</sup> a total reduction in wound area of 90%. The wound bed was assessed as 100% granulation tissue. The surrounding tissue was healthy. Exudate levels were low.

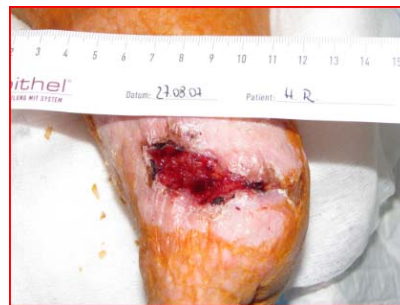

Fig.6. Wound at week 6

### COMMENT

There was a total wound reduction of 90% over the 6 week period. Exudate levels decreased. There was a general improvement in the condition of the wound.

### SATISFACTION

The clinician assessed the wound as being much improved.

The patient described the dressing as very comfortable during application and treatment, and was very satisfied with the Oxyzyme dressing. (Oxyzyme continued to be used as the treatment of choice following the end of the study.)

**OXYZYME<sup>®</sup> CASE STUDY PROGRAMME**  
OXY-CS001-18/06: THE USE OF OXYZYME<sup>®</sup> ON  
CHRONIC WOUNDS

